

TREATMENT WITH A POLYCHROMATIC PULSED LIGHT DEVICE FOR A DYSFUNCTION DESCRIBED AS “DRY EYE” IN THE FORM OF A CORNEAL CONDITION ASSOCIATED WITH A DEFICIENCY IN THE LIPID LAYER

Dr Christian MALBREL, Ophthalmologist

Anatomical review

The lachrymal film, which is necessary for the functioning of the eye, is comprised of three layers:

- a mucus layer in contact with the eyeball, secreted by the conjunctival mucus cells
- an aqueous layer, secreted by the lachrymal glands
- a lipid layer, secreted by the intratarsal Meibomian cells

The Meibomian cells, approximately 80 in number, are arranged in the tarsus of the upper and lower eyelids, and discharge at the level of the grey line, behind to the lashes.

These cells secrete a lipid phase, the function of which is to prevent the evaporation of tears, to adapt to surface changes associated with blinking, and to deliver an optical function by the maintenance of a perfectly convex diopter.

The lipids are comprised of polarized fatty acids, the fluidity of which is maintained by the body temperature, and unpolarized at the surface, thereby maintaining the stability of the lachrymal fluid and ensuring the lubrication of the palpebral conjunctival surface. The contraction of Riolan's muscle ensures the spreading of the lachrymal film.

Dysfunction of the Meibomian glands

Impairment of the lipid phase secreted by these cells will result in the excessive evaporation of tears, instability in the lachrymal film and an inflammatory reaction of the conjunctiva.

The result will be an increasing visual impairment during prolonged tasks involving close-up vision (work on VDUs), with sensations of burning or the presence of foreign bodies which will oblige the sufferer to interrupt the task in progress.

If this process accelerates, the resulting discomfort will become permanent, leading to paradoxical watering which will make it impossible to wear contact lenses.

Anatomical changes may occur in conjunction with the atrophy of the outlet ducts of the Meibomian glands, punctuated by infectious episodes – styes, chalazions, secondary conjunctival infections – and, in the most severe cases, damage to the cornea.

Current treatments

A variety of therapeutic treatments are available, according to the severity of functional symptoms and the daily discomfort experienced by patients:

- lachrymal substitutes, in the form of eye lotions or creams
 - occlusion of the lachrymal points
 - moisture chamber spectacles
 - treatment by antibiotics – local and general
 - treatment by cortisone cream
 - treatment by cyclosporin
 - treatment by dietary supplements
 - cleansing treatments
- Lachrymal substitutes are easily obtainable and available at any time, and provide immediate relief; however, their effectiveness is often short-term, requiring the frequent application of treatments. Their administration may be more difficult for older patients, or for those whose manual dexterity is impaired (where arthritis in the hands prevents the squeezing of the bottle, or rheumatism in the shoulders prevents the lifting of the arms). The cost of these treatments will rapidly become substantial, as they are subject to only limited reimbursement, if any.
- Meiotic plugs can be used for the occlusion of the inferior lachrymal point, and deliver an improvement associated with the reduction of the consequences of evaporation. For some patients, they have the disadvantage of a permanent irritation associated with rubbing contact on the conjunctiva of the eyeball each time the eye is closed. They are easily lost, and cost in the region of 130 euros per pair, subject to 65% reimbursement.
- Moisture chamber spectacles can theoretically eliminate evaporation and improve the quality of the lipid fraction. However, they cannot be worn for more than a few minutes at a time and cost 220 euros per pair, which is not subject to reimbursement.
- Treatment with local and general antibiotics can combat the secondary infection which is frequently associated with this type of pathology. This treatment can relieve the symptoms associated with rosaceous acne. However, this is a complementary treatment only. Severe allergic reactions are frequently encountered.

- Local and, in some cases, general corticotherapy can relieve the inflammatory element of the condition, and is frequently effective in application. As a result of side effects – secondary infections, can occur such as ocular hypertonia, cataracts – therefore this is not a long-term treatment solution.
- Cyclosporin is highly effective for the most severe forms of the condition. Cyclosporin is not commercially available, and is difficult to obtain. Tolerance of cyclosporin is mediocre.
- Dietary supplements are useful for patients who suffer from a deficiency of essential fatty acids. These supplements are not subject to reimbursement.
- Cleansing treatments are essential. Their effectiveness is limited and they are not subject to reimbursement.

Treatment of dry eye using PPL

Device used

The device used, the E-EYE model produced by the company E-SWIN, generates a polychromatic pulsed light.

Forms of treatment

In the majority of cases, treatment application is straightforward.

Treatment of the tarsal element of the lower eyelids, applied to the cutaneous flank, is the basic option for treatment:

4 charges are applied, sweeping the lower eyelid from the outer canthus to the inner canthus, at a power rating of 13 joules.

For the treatment of skins with a high phototype (4 and 5, according to the Fitzpatrick classification system), or if the patient is deeply tanned, the flux density should be reduced by 1 to 3 J/cm², in order to avoid any deleterious effects upon melanocytes.

In the most severe cases, however, it may be necessary to treat all four eyelids simultaneously. In this case, following local anaesthesia by the administration of Tetracaine®, metal shells, previously coated with an ophthalmic gel, will need to be placed upon the eyeball. These shells are removed subsequently using a ventouse.

Accordingly, the patient must be warned of a temporary disturbance of vision associated with the gel, will need to be accompanied upon their departure from the surgery, and will be prohibited from driving for one hour thereafter.

For optimum sequencing, following the first treatment session, a second session should be administered two weeks later, followed by one session per month thereafter until the symptoms are cleared.

Protection and safety

The skin is protected by the application of a thick pad of cold hydrogel.

The eyeball of the patient under treatment is protected by a metal eye shield. The operator must also wear appropriate eye protective equipment, as must any other person presents in the treatment room.

Ideally, the patient should be reclined on a treatment table. This will ensure the greater comfort of the patient, and will facilitate the administration of treatment by the practitioner.

Results of E-EYE PPL treatment

PPL stimulation induces the restoration of the normal activity of the Meibomian glands, with a very rapid subjective improvement for the patient in the hours following treatment. This improvement lasts for approximately one week following the initial treatment, for two to three weeks after the second and third treatments, and thereafter for several months, in response to the cumulative effects of treatment.

The effectiveness of treatment is virtually constant for all conditions affecting the Meibomian glands – this is not true of conditions associated with an isolated impairment of the aqueous phase or the mucus phase, or in case of an associated secondary infection, which must be treated beforehand.

Perceived effectiveness

Results obtained for a cohort of 80 patients aged between 21 and 90 years, with an average age of 67, with no preselection and representative of the “standard” patient register of an independent practice, show a significant subjective improvement, with satisfaction of the order of 90% following the first two treatment sessions.

This improvement is established on the basis of the patient’s opinion of the discomfort experienced before and after the application of treatment and the associated focusing time, whether for reading or for work on a VDU. After the first treatment, this improvement is experienced for a number of days, and will only become more prolonged after the second and subsequent treatments.

Quantitative results

For objective assessment, the Oxford classification may be appropriately applied, with five levels for fluorescein instillation:

For this examination, the natural surface condition of the patient's cornea and conjunctiva will be observed, followed by the instillation of one drop of fluorescein, with no associated anaesthesia.

Excess tears are removed, and the dye is allowed to spread for one minute – the break-up time of the lachrymal film is then observed, together with the appearance of micropunctuations which are coloured by fluorescein under blue light.

0 – a number of punctuations on the outer edge: minor discomfort for the patient

1 – micropunctuations on the lower part of the cornea: difficulty in reading for long periods

2 – micropunctuations on the lower quarter of the cornea: difficulty in focusing

3 – micropunctuations on the visual axis and the horizontal edge: permanent discomfort

4 – micropunctuations over the entire corneal surface: disability.

In the group of patients studied, after the passage of more than two months and a number of treatment sessions equal to or greater than three, observations were as follows:

Stage	Upon initial examination		Upon final examination	
	Patients	%	Patients	%
0	6	08%	33	41%
1	31	39%	18	23%
2	31	39%	17	21%
3	7	09%	7	09%
4	5	06%	5	06%
Total	80		80	

Development:

Upon final examination:

- 33 patients, or 41%, are classified at stage 0:

- ✓ 6 from group 0
- ✓ 21 from group 1
- ✓ 6 from group 2

- 23%, or 18 patients, are classified at stage 1:

- ✓ 10 from group 1
- ✓ 8 from group 2

There was no variation in either group 3 or group 4.

No patient had deteriorated.

If we consider only those patients who, prior to treatment, were classified at stages 1 and 2 and who represent the target population for this type of treatment, the development observed was as follows:

Stage	Upon initial examination		Upon final examination	
	Patients	%	Patients	%
0	-		27	44%
1	31	50%	18	29%
2	31	50%	17	27%
Total	62	100%	62	100%

- 45% of stage 2 patients improved by one or more grades.
- 81% of stage 1 patients improved by one grade.

It should be noted that patients initially classified in group 0, and who could not be subject to any objective improvement after treatment – as the Oxford classification does not include any stage lower than 0 – all reported an improvement in their perceived discomfort.

Glare test

The object of this test is the quantification of the improvement in visual function after treatment by more extensive documentation than that associated with the grading of corneal punctuation of the perceived improvement of the patient.

This test has numerous clinical applications: the early detection of cataracts, determination of the pre-surgical and post-surgical refractive index, evaluation of aptitude for night driving, etc.

For the execution of this test, a stimulator is equipped with lateral sources of glare on either side of the screen. The result is delivered in the form of a score, which corresponds to the number of letters which are correctly identified by the patient. The sensitivity of the test can be particularly enhanced by the use of optotypes with a low level of luminance on a dark background. Provision is made for three levels of luminance: 1 cd/m², 5 cd/m² and 100 cd/m². The 1 cd/m² level is intended for normal subjects, while the 5 cd/m² and 100 cd/m² levels are intended for subjects with impaired vision.

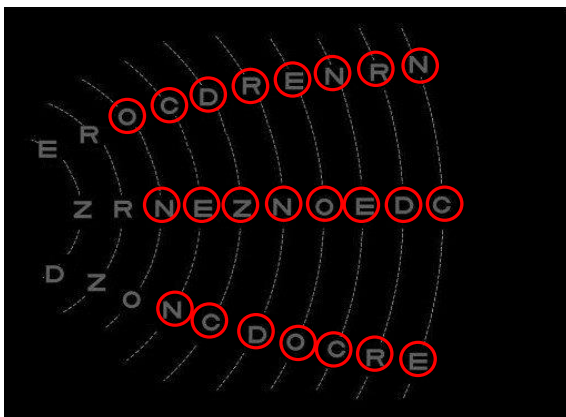
The lateral positioning of a source of glare in relation to the eye tested increases the difficulty of the reading test and simulates conditions encountered in everyday life, such as the night-time driving of a vehicle, where the driver will be exposed to the glare of headlights coming in the opposite direction. In this test, the discomfort described by patients suffering from ocular dryness is associated with a very clear impairment of performance, in relation to the testing of visual acuity under normal conditions.

It will be seen that this test is more sensitive, as patients of the type represented by cases 1 and 2 below show a significant improvement in visual function, whilst remaining at the same stage of corneal punctuation:

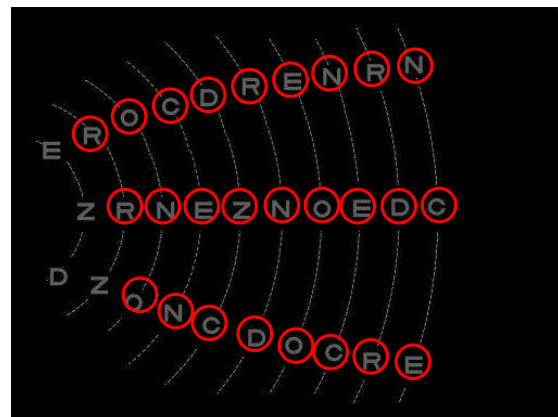
Conclusions and recommendations

From these results, the effectiveness of the E-EYE treatment is clear, with a rapid return to the least disabling clinical forms. Although there is little impact upon the most severe forms, this is not the principal intended purpose of the treatment.

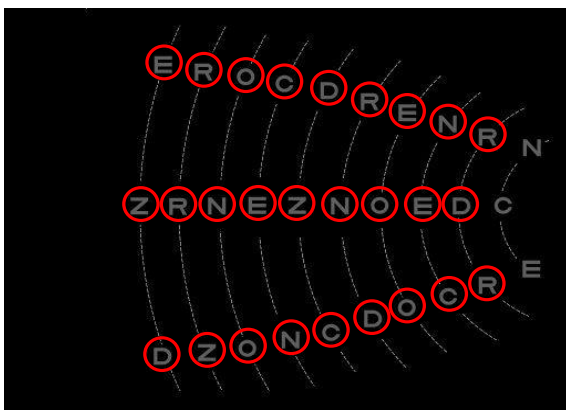
Accordingly, this treatment should be accessible to the maximum number of patients in France, estimated at around one million.



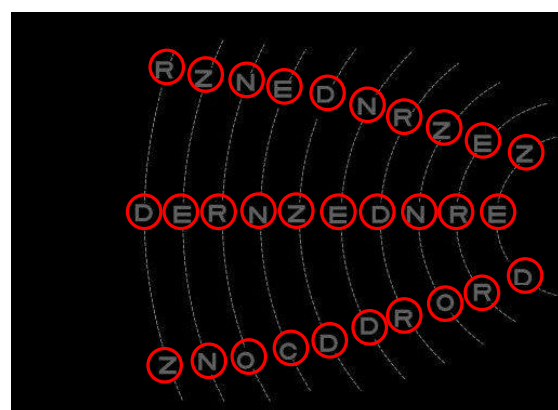
score = 76,7% 5 cd/m2 2.5 m
Cornea: grade 1 og
Impaired glare test
Patient 1



score = 86,7% 5 cd/m2 2.5 m
Cornea: grade 1, 3 weeks after a single treatment
Improvement in glare test for the left eye
Patient 1



score = 90,0% 5 cd/m2 2.5 m
Initial test for right eye, average impairment
Cornea: grade 1
Patient 2



score = 100,0% 5 cd/m2 2.5 m
Test one month after a single treatment, cornea still grade 1
Return to normal
Patient 2

The process is easy to use, and avoids any endangerment to the vision of the patient, provided that the eyeballs and skin are correctly protected.

The machine is straightforward to operate, and the read-outs from the various windows are easily comprehensible. The service frequency is satisfactory. An attempt should ideally be made for the reduction of noise during cooling, particularly where the hand-held component is resting on its base.

The gel for application to the skin should ideally be provided in the form of a disposable pad, to be refrigerated where applicable, of sufficient thickness to adapt to the contours of the zone treated and be substantially stable under pressure, in order to ensure the effective application of treatment and to avoid any cutaneous damage associated with the emission of heat.

Finally, particular attention will need to be paid to the ocular protection system, in the form of a pair of metal eye shields which are easy to use, adaptable to the morphology of the patient, and easy to disinfect.

ooooo

Study undertaken by Dr Christian MALBREL,
Ophthalmologist

Former director of studies at the Reims Faculty of
Medicine
Former senior clinical assistant at the Reims Faculty of
Medicine
Inter-university graduate in morphological and anti-ageing
medicine from the Bobigny Faculty of Medicine